

Case Report

# Nail in chilblains – Clinical and onychoscopic findings with review of literature

Prathibha Kuchana, MBBS<sup>1</sup>, Shikha Bansal, MD, DNB<sup>1</sup>

<sup>1</sup>Department of Dermatology and STD, Vardhman Mahavir Medical College and Safdarjung Hospital, New Delhi, India.

## ABSTRACT

Chilblains, characterised by an abnormal vascular response to cold and damp conditions, leads to cutaneous and nail changes. Though a common entity and a mimicker of other dreadful conditions, less data is available regarding nail changes in chilblains. We report nail findings and onychoscopic features in two patients with chilblains, a middle-aged female and a male. Clinical examination revealed tender violaceous plaques involving the lateral nail folds, dystrophy of the nail plate, distal subungual hyperkeratosis, erythronychia, splinter haemorrhages, hypopigmented scarring, nail pallor, and distal onycholysis. Onychoscopy revealed distorted lunulae, distal onycholysis, splinter haemorrhages, nail pallor, microhemorrhages involving periungual areas and nail-bed erythema. A knowledge of nail changes and onychoscopic findings in a common entity like chilblains, is essential for differentiating mimickers (including nail lichen planus, subungual melanoma) and initiating appropriate treatment.

**Keywords:** Chilblains, Winter exacerbations, Nail, Onychoscopy, Nail-fold capillaroscopy

## INTRODUCTION

Chilblains, also known as pernio, is an inflammatory condition characterised by an abnormal vascular response to cold and damp conditions. Vasospasm likely plays a role in its pathophysiology.<sup>[1]</sup> An extensive literature search showed few reports of nail findings in pernio, and none reported its onychoscopic findings. We report nail findings and onychoscopic features in two cases of chilblains.

## CASE REPORT

### Case 1

A 33-year-old female presented with complaints of cold hands and feet in winters. She had developed painful, itchy, bluish lesions involving both hands, along with fluid-filled blisters for 3 days. The patient was a housekeeper by occupation; hence, had a history of immersing her hands in cold water. A history of similar episodes in the past with exacerbations in winters was present. All 20 nails were examined in a well-lit room with the fingers resting gently over the table. Tender violaceous plaques were seen involving the lateral nail folds. There were clear fluid-filled vesicles and bullae, arising over an erythematous to violaceous background, involving the

dorsal aspect of the fingers. These were in contiguity with the proximal nail folds. Dystrophy of the nail plate with distal subungual hyperkeratosis, erythronychia, and splinter haemorrhages were also seen [Figure 1a and b]. Onychoscopy (DermLite DL4, 3Gen Inc, CA, USA) accentuated the clinical features along with pale proximal nail folds, distorted lunulae, marginal yellowish discolouration, nail-bed erythema, splinter haemorrhages and distal onycholysis [Figure 2]. Nail-fold capillaroscopy showed a sparsening of blood vessels in nine nails, with five nails showing avascular areas.

### Case 2

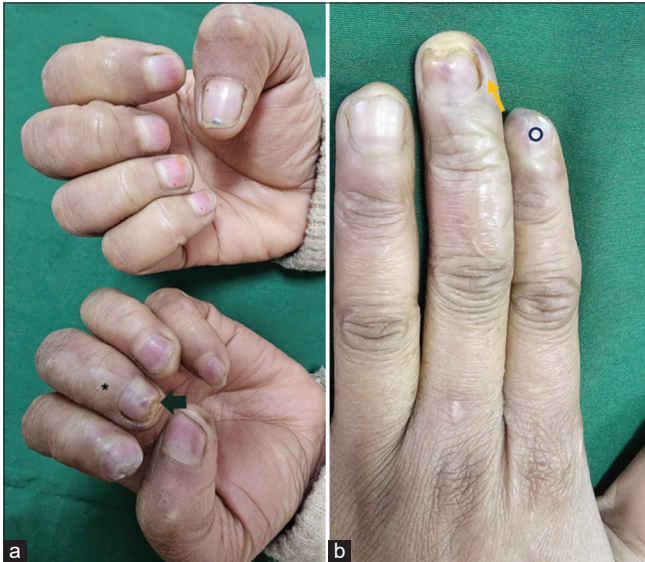A 57-year-old male presented with painful erosions and reddish, itchy lesions involving fingers for 7 days. The patient was a car washer by occupation and gave a history of immersing his hands in cold water. A history of similar episodes was present in the past, with exacerbations every winters. On examination, a tender violaceous plaque was noted over the left thumb. Erosions were seen with a yellowish crust over a violaceous background, involving the dorsal aspect of other fingers. Hypopigmented scarring was seen involving the periungual areas and distal portion of all fingers. There was nail pallor, distal onycholysis [Figure 3] and longitudinal melanonychia.

\*Corresponding author: Shikha Bansal, MD, DNB, MNAMS, Professor, Department of Dermatology and STD, Vardhman Mahavir Medical College and Safdarjung Hospital, New Delhi, India. [contactshikha@rediffmail.com](mailto:contactshikha@rediffmail.com)

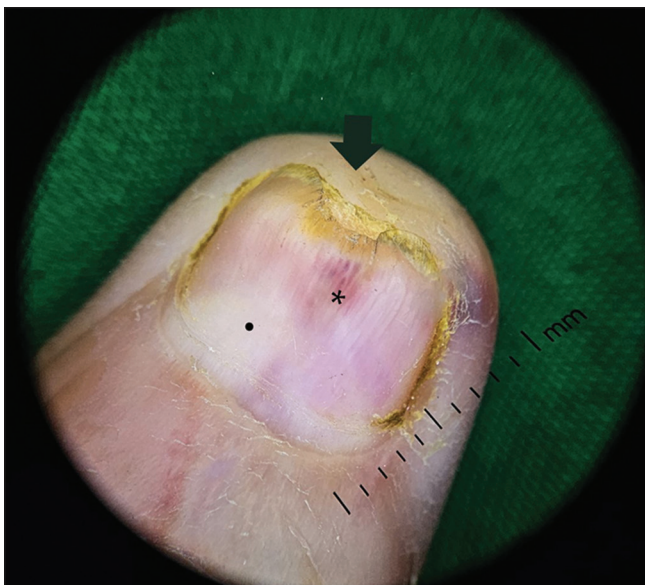Received: 04 September 2024 Accepted: 15 September 2024 Epub Ahead of Print: 04 February 2025 Published: XXXXXXXXXX DOI: 10.25259/JONS\_17\_2024

This is an open-access article distributed under the terms of the Creative Commons Attribution-Non Commercial-Share Alike 4.0 License, which allows others to remix, transform, and build upon the work non-commercially, as long as the author is credited and the new creations are licensed under the identical terms.

©2025 Published by Scientific Scholar on behalf of Journal of Onychology and Nail Surgery

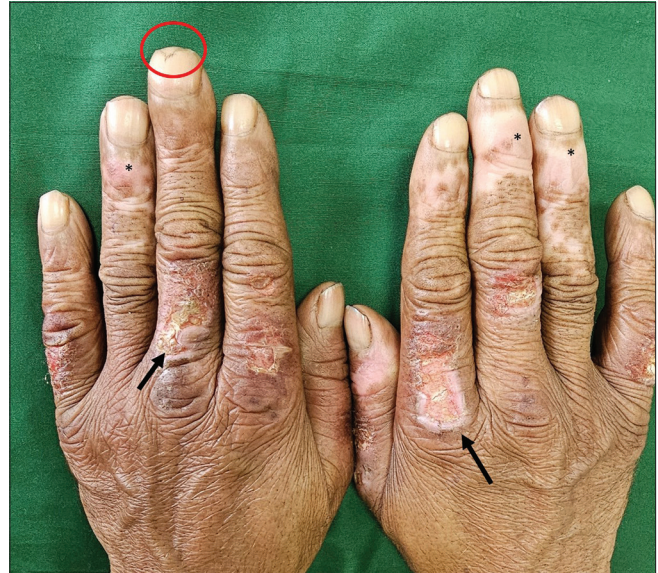

**Figure 1:** 33-year-old woman presenting with chilblains. (a) Clinical image showing clear fluid-filled bullae over dorsal aspect of fingers of the left hand, seen in contiguity with proximal nail-fold (\*) erythronychia (black arrow). (b) Clinical image showing dystrophy of the nail plate (circle), distal subungual hyperkeratosis and erythronychia with splinter haemorrhages along with violaceous plaque over lateral nail fold (yellow arrow).

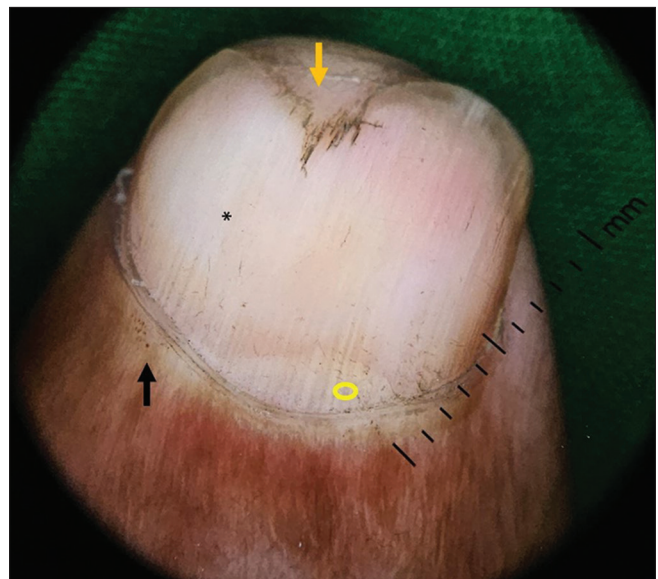


**Figure 2:** Onychoscopy showing distal onycholysis, marginal yellowish discoloration, nail-bed erythema (black arrow), splinter haemorrhages (\*), and distorted lunula (.) in the first case.

Onychoscopy (DermLite DL4, 3Gen Inc, CA, USA) showed distorted lunula, distal onycholysis, splinter haemorrhages, nail pallor, microhemorrhages involving proximal nail fold [Figure 4], and longitudinal melanonychia (predominantly toenails). Nail-fold capillaroscopy showed microhemorrhages and avascular areas.



**Figure 3:** 57-year-old man who presented with chilblains, clinical image showing fingers with tender violaceous plaque, erosions with crusting (arrow), hypopigmented scarring over periungual and distal areas (\*), distal onycholysis and nail pallor (circle).



**Figure 4:** Onychoscopy of the left middle finger showing distorted lunula (circle), distal onycholysis (yellow arrow), nail pallor (\*) and microhemorrhages over proximal nail fold (black arrow) in the second case.

## DISCUSSION

Chilblains or pernio usually presents as pruritic or painful erythematous and violaceous papules, plaques or vesicles involving acral areas, on exposure to cold and humid conditions.<sup>[2]</sup> The disease is typically idiopathic and acute; however, chronic forms also exist. Secondary pernio has been associated with other conditions, the most common being systemic lupus erythematosus (chilblain lupus erythematosus

**Table 1:** Published literature on nail findings in chilblains.

Published literature	Nail findings in chilblains
Hwang <i>et al.</i> <sup>[4]</sup> 2012	Post-inflammatory melanonychia involving nails
Singh <i>et al.</i> <sup>[5]</sup> 2018	Anonychia, longitudinal fibrotic bands and pterygium formation
Ozuguz <i>et al.</i> <sup>[6]</sup> 2014	Hyperaemic ground, with slight purple in colour, longitudinal ridges
Lambertini <i>et al.</i> <sup>[7]</sup> 2018	Atrophic and partially ulcerated nail bed, with destroyed nail plates.

or CHLE).<sup>[3]</sup> Chronic or severe cases of chilblains may be associated with chronic damage to the nail matrix, leading to nail deformities. These signs and symptoms should be differentiated from other conditions including Raynaud's disease, lupus pernio, livedo reticularis and acrocyanosis. None of our patients had a history of cyanosis, or pallor, and both of them gave a history of winter exacerbation of their condition. Hwang *et al.*<sup>[4]</sup> reported post-inflammatory melanonychia due to recurrent chilblains, likely as a post-inflammatory phenomenon. One of our patients had longitudinal melanonychia involving toenails, with onset of pigmentation after the episodes of chilblains. Hypopigmentation and scarring in periungual areas is associated with the chronicity of the condition. Singh *et al.*<sup>[5]</sup> reported two cases of nail involvement in chilblains, with total anonychia involving almost all the digits. In addition, longitudinal fibrotic bands and pterygium mimicking nail lichen planus, have been described. The authors postulated that chronic vasoconstriction leading to nail matrix ischemia is a cause of these nail changes. In 2014, Ozuguz *et al.*<sup>[6]</sup> reported a case of chilblains in a construction worker with nail changes, including hyperaemic background, slight purple colour and longitudinal ridges. The authors concluded that in chronic and severe cases of pernio, an inflammatory response can lead to damage to the nail matrix. Lambertini *et al.*<sup>[7]</sup> also reported a case of chilblain lupus with nail involvement with atrophic and partially ulcerated nail beds and destroyed nail plates. Nail-fold capillaroscopy showed microvascular changes, including tortuous capillaries, enlarged capillaries and/or microhemorrhages. Manuelyan *et al.*<sup>[8]</sup> reported an interesting case of single nail dystrophy in a patient with blue discolouration of several toes. The nail changes in this patient had been considered to be secondary to chilblains, leading to a delay in the diagnosis of amelanotic subungual melanoma. Table 1 showing published literature on nail findings of chilblains.

## CONCLUSION

Knowledge of nail changes and onychoscopic findings in a common entity like chilblains is essential for making an accurate diagnosis and initiating appropriate treatment. The

mimickers of nail changes in chilblains vary from lichen planus to subungual melanoma.

## Authors' contributions

Both the authors have contributed equally in diagnosis, management, and preparation of the manuscript.

## Ethical approval

The research/study approved by the Institutional Review Board at Vardhman Mahavir Medical College and Safdarjung Hospital, number IEC/VMMC/SJH/Case-Report/Aug-2024/01, dated 03 August 2024.

## Declaration of patient consent

The authors certify that they have obtained all appropriate patient consent.

## Financial support and sponsorship

Nil.

## Conflicts of interest

Dr. Shikha Bansal is on the editorial board of the Journal.

## Use of artificial intelligence (AI)-assisted technology for manuscript preparation

The authors confirm that there was no use of artificial intelligence (AI)-assisted technology for assisting in the writing or editing of the manuscript and no images were manipulated using AI.

## REFERENCES

- Shahi V, Wetter DA, Cappel JA, Davis MD, Spittell PC. Vasospasm is a consistent finding in pernio (chilblains) and a possible clue to pathogenesis. *Dermatology* 2015;231:274-9.
- Goette DK. Chilblains (pernio). *J Am Acad Dermatol* 1990;23(2 Pt 1):257-62.
- Whitman PA, Crane JS. Pernio. In: StatPearls. Treasure Island, FL: StatPearls Publishing; 2024.
- Hwang JI, Kim JE, Park HJ, Cho BK. Postinflammatory melanonychia due to chilblain. *Int J Dermatol* 2012;51:1010-1.
- Singh A, Bhatia S, Gupta S. Nail changes in chilblains mimicking lichen planus. *J Clin Exp Dermatol Res* 2018;9:464.
- Ozuguz P, Kacar SD, Karaca S. Does pernio cause nail dystrophy? *J Pak Med Assoc* 2014;64:349-50.
- Lambertini M, Vincenzi C, Dika E, La Placa M. Chilblain lupus with nail involvement: A case report and a brief overview. *Skin Appendage Disord* 2018;5:42-5.
- Manuelyan K, De Silva B, Singh-Raghunath R. Amelanotic subungual melanoma and chilblains. *BMJ Case Rep* 2023; 16:e252791.

**How to cite this article:** Kuchana P, Bansal S. Nail in chilblains – Clinical and onychoscopic findings with review of literature. *J Onychol Nail Surg.* doi: 10.25259/JONS\_17\_2024