

Letter to Editor

Brachyonychia in a scleroderma patient with Grade 3 renal parenchymal disease and interstitial fibrosis

Rhea Ghorui, MBBS,¹ Pavithra Gundappa, MD.¹

¹Department of Dermatology Venereology Leprosy, Sri Siddhartha Medical College, Tumakuru, Karnataka, India.

Dear Editor,

Scleroderma is a rare, complex autoimmune multi-system disorder characterised by skin induration and organ involvement, which mostly affects females around 4th or 5th decade of life.^[1] It can involve the skin, joints, muscles and internal organs such as the lungs, kidneys and gastrointestinal tract. Lung complications in scleroderma can occur in the form of pulmonary arterial hypertension and interstitial fibrosis. The most common internal organ involved is the gastrointestinal tract, whereas the most dreaded complication is the scleroderma renal crisis.^[2]

Although nail fold capillaroscopy plays a key role in the diagnosis, nail changes are uncommonly described in autoimmune connective tissue disorders. These include splinter haemorrhages in systemic lupus erythematosus, red lunula in rheumatoid arthritis and ragged cuticles in dermatomyositis.^[3] The common nail changes described in scleroderma are pterygium inversum, trachyonychia, thickened nails and splinter haemorrhages.^[4]

Brachyonychia refers to a nail with greater width than length. The causes of brachyonychia are varied and can be classified as genetic (autosomal dominant inheritance), or acquired. The main cause of brachyonychia is acroosteolysis or bone resorption. Acroosteolysis can be due to vascular changes, as seen in scleroderma and Raynaud's phenomenon. It may also be seen with neuropathic changes (as seen in leprosy) or metabolic changes (as seen in diabetes, hyperparathyroidism, rickets, osteomalacia and chronic kidney disease).^[5] There are many genetic causes of brachyonychia, which are rare and in most cases present at birth; although, some changes may present later in childhood, including Larsen syndrome, Brooke–Spiegler syndrome and Rubinstein–Taybi syndrome.^[6] In this study, we present a case of brachyonychia due to acrosclerosis secondary to Raynaud's phenomenon, in a scleroderma patient.

A 40-year-old female patient presented with complaints of breathlessness for 1 week, pain in the abdomen, and vomiting for 2 days. The patient also gave a positive history of Raynaud's phenomenon on exposure to cold. There was no history of new drug intake for weight loss. She was hypertensive for 5 years and on antihypertensives.

The patient was moderately built and poorly nourished. She was conscious, cooperative, and well-oriented to time, place and person. The patient's bowel and bladder activities were regular. There were no signs of pallor or icterus. On systemic examination, bilateral coarse crepitations were heard over the suprascapular region. Pulmonary function tests revealed a restrictive pattern with low forced vital capacity and low residual volume.

Cutaneous examination revealed fish-mouth aperture and immobile facies [Figure 1], salt pepper pigmentation over the neck [Figure 2], sclerodactyly and acrosclerosis over the fingers [Figure 3] with digital ulcers and scars over the interphalangeal joint of hands. Moderate thickening of skin involving the digits and upper limbs was seen with Ingram sign and Mizutani sign being positive.

Nail findings showed the presence of racquet nails in all 10 digits of the upper limb [Figure 3]. Lower limb nails were normal [Figure 4]. Nail fold capillaroscopy (Dermlite DL5 dermatoscope, 3Gen Inc, CA, USA) revealed normal-shaped capillaries and a limited number of giant capillaries with a well-preserved capillary distribution [Figure 5].

Basic investigations revealed increased white blood cell counts, increased erythrocyte sedimentation rate, and deranged renal function test with increased urea and creatinine. Serum electrolytes were deranged with decreased sodium and chloride. However, her serum calcium, phosphorus levels, liver function tests, thyroid function tests, parathyroid hormone, urine routine, microscopy and

*Corresponding author: Rhea Ghorui, Department of Dermatology Venereology Leprosy, Sri Siddhartha Medical College, Tumakuru, Karnataka, India. rheaghorui@gmail.com

Received: 29 July 2024 Accepted: 26 August 2024 Published: 29 November 2024 DOI: 10.25259/JONS_3_2024

This is an open-access article distributed under the terms of the Creative Commons Attribution-Non Commercial-Share Alike 4.0 License, which allows others to remix, transform, and build upon the work non-commercially, as long as the author is credited and the new creations are licensed under the identical terms.

©2024 Published by Scientific Scholar on behalf of Journal of Onychology and Nail Surgery

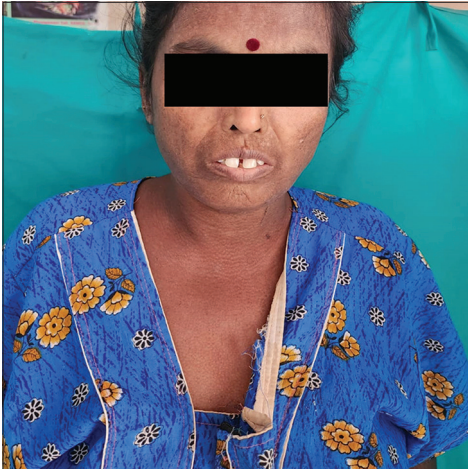

Figure 1: 40-year-old woman with scleroderma, presenting with fish mouth aperture.

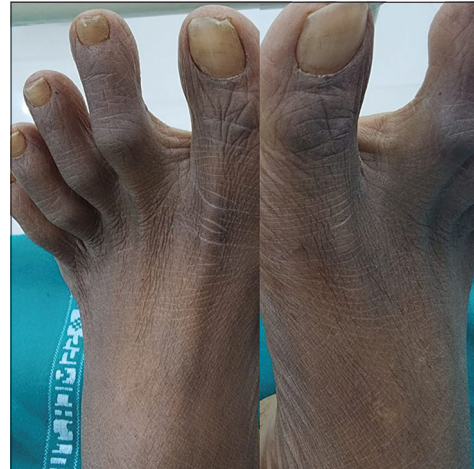

Figure 4: Nails of bilateral toes.

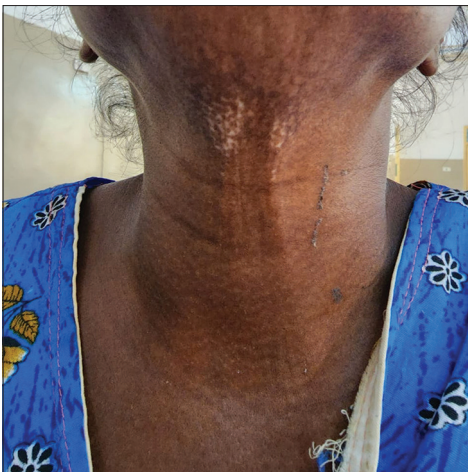

Figure 2: Salt and pepper pigmentation over the neck with Barnett's neck sign positive.



Figure 5: Nail fold capillaroscopy over the third digit nail fold (DermLite DL5) revealing early systemic sclerosis changes. (Polarised 10x).

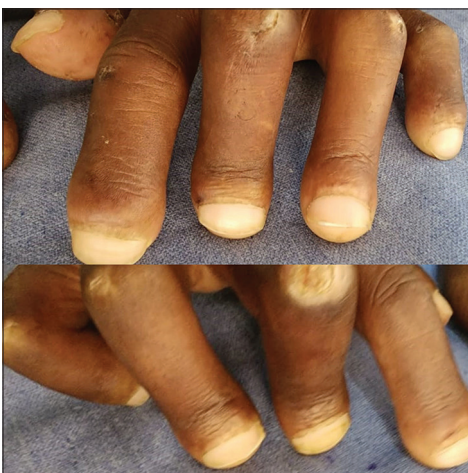

Figure 3: Acrosclerosis involving the fingers with racquet nails.

serology were normal. Anti-nuclear antibody titers were high. Chest X-ray revealed interstitial lung disease [Figure 6] and ultrasonography of the abdomen detected Grade 3 renal parenchymal disease. Skin biopsy and histopathological examination showed subcutaneous fat being replaced by fibrous connective tissue, densely packed collagen bundles and effacement of rete ridges. A diagnosis of scleroderma was made [Figure 7].

To summarise, scleroderma can present with multiple skin and nail manifestations. Although nail involvement is recognised in scleroderma with pterygium inversum, trachyonychia, thickened nails and splinter haemorrhages being reported; brachyonychia or racquet nails are an uncommon finding in these patients. Brachyonychia in this case is primarily attributable to vascular changes resulting in hypoxia and elevated levels of cytokines, increasing the activity of osteoclasts and resulting in bone resorption. Our patient's serum calcium and phosphorus levels were normal, indicating no secondary cause of brachyonychia as seen in hyperthyroidism and chronic kidney disease.

To conclude, nail changes play an important role in the

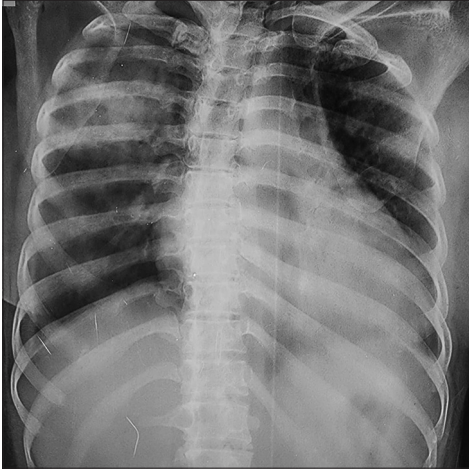


Figure 6: Chest X-ray revealing interstitial fibrosis.

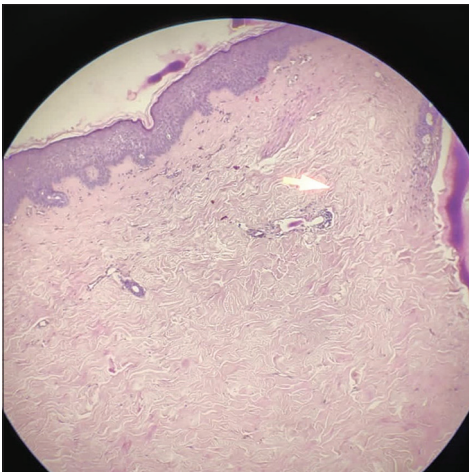


Figure 7: Histopathology showing subcutaneous fat replacement by fibrous connective tissue, densely packed collagen bundles (as indicated by the white arrow), and effacement of rete ridges (H&E x100).

diagnosis of certain skin disorders. Hence, their early detection is vital in the assessment of the severity and prognosis of these disorders.

Authors' contributions

Both authors contributed towards the concept, design, collection and processing of data, analysis and interpretation, literature search, writing.

Ethical approval

The Institutional Review Board approval is not required.

Declaration of patient consent

The authors certify that they have obtained all appropriate patient consent.

Financial support and sponsorship

Nil.

Conflicts of interest

There are no conflicts of interest.

Use of artificial intelligence (AI)-assisted technology for manuscript preparation

The authors confirm that there was no use of artificial intelligence (AI)-assisted technology for assisting in the writing or editing of the manuscript and no images were manipulated using AI.

REFERENCES

1. Altan G, Kose TE, Erdem TL, Ozcan I. Scleroderma: A case report. *J Istanb Univ Fac Dent* 2015;49:31-4.
2. Sobolewski P, Maślińska M, Wieczorek M, Łagun Z, Malewska A, Roszkiewicz M, *et al.* Systemic sclerosis - multidisciplinary disease: Clinical features and treatment. *Reumatologia* 2019;57:221-33.
3. Elmansour I, Chiheb S, Benchikhi H. Nail changes in connective tissue diseases: A study of 39 cases. *Pan Afr Med J* 2014;18:150.
4. Marie I, Gremain V, Nassermadji K, Richard L, Joly P, Menard JE, *et al.* Nail involvement in systemic sclerosis. *J Am Acad Dermatol* 2017;76:1115-23.
5. Baran R, Turkmani MG, Mubki T. Acquired racquet nails: A useful sign of hyperparathyroidism. *J Eur Acad Dermatol Venereol* 2014;28:257-9.
6. Rosales Figueroa JD, Chang P. Brachyonychia associated with acroosteolysis in chronic kidney disease: How phalange shape influences nail morphology. *Skin Appendage Disord* 2018;4:264-7.

How to cite this article: Ghorui R, Gundappa P. Brachyonychia in a scleroderma patient with Grade 3 renal parenchymal disease and interstitial fibrosis. *J Onychol Nail Surg.* 2024;1:55-7. doi: 10.25259/JONS_3_2024