

Case Series

Benign longitudinal melanonychia in skin of color: A case series

Mohd Shurjeel Ul Islam, MD.¹, Najam u Saqib, MD.¹, Sushma Danusari, MBBS.¹, Kurat Sajad, MD.¹, Yasmeen Jabeen Bhat, MD.¹

¹Department of Dermatology, Venereology and Leprosy, Government Medical College, Srinagar, Jammu and Kashmir, India.

ABSTRACT

Longitudinal melanonychia is characterised by pigmented bands on the nail caused by the activation or proliferation of melanocytes. We present a case series of five Indian patients with skin of color with benign longitudinal melanonychia diagnosed through dermoscopy. Patients aged 25–39 years presented with longitudinal bands on their thumbnails of varying colours and sizes for 6–18 months. The dermoscopic evaluation revealed regularly arranged parallel lines of uniform colour and spacing with a positive pseudo-Hutchinson sign. This study emphasises the utility of dermoscopy in distinguishing benign from malignant longitudinal melanonychia in skin of color, and its role in monitoring lesions and detecting malignant changes at the earliest.

Keywords: Benign, Longitudinal melanonychia, Pseudo-Hutchinson

INTRODUCTION

Longitudinal melanonychia is a clinical condition characterised by a pigmented band that runs longitudinally along the nail bed, typically presenting as brown or black lines on fingernails or toenails. This phenomenon is due to increased melanin production, which causes pigmentation. It more commonly involves darker skin types.^[1,2] Here, we present a series of five cases of longitudinal melanonychia diagnosed with dermoscopy.

CASE SERIES

Five cases of longitudinal melanonychia with dermoscopy findings included 3 patients in their–30s and the other two in their mid-20s. There were no known comorbidities in four patients, while one patient had a type II diabetes mellitus and onychomycosis under treatment. All patients presented to our outpatient department with discolouration of their fingernails for 6–18 months. On examination, we found longitudinal linear pigmented bands of variable size and colour in the thumbnails. The rest of the nail apparatus was apparently normal except for one case with subungual hyperkeratosis. There was no history of past trauma, infections, or drugs except one patient who was on antidiabetic agents and antifungals. Dermoscopy (Dermlite DL4, polarised, ×10)

revealed a pigmented band (black or brown) with regularly arranged parallel lines of similar colour, regular spacing, and diameter, with pseudo-Hutchinson sign seen in all patients. Figures 1 and 2 and Table 1 demonstrate the clinical and dermoscopic findings of five patients.

DISCUSSION

Melanonychia is derived from the Greek word ‘Melas’, meaning black or brown, and ‘Onyx’, meaning nail. Melanonychia is a brown/black discoloration of the nail.^[3] It can be longitudinal (melanonychia striata), diffuse (total melanonychia) or transverse melanonychia. It can present in individuals of all ages, affecting both sexes equally, with a prevalence of 0.8%.^[4] It is more commonly seen in skin of color, especially Fitzpatrick Risk factors include genetic disorders, injury, medications, nutritional deficiency, endocrine disease, connective tissue disease, inflammatory skin disease, local tumours, or nail infections.^[3]

The pathophysiology of longitudinal melanonychia involves melanocyte activation or proliferation (nevus/melanoma). Melanocytes lie dormant in the proximal nail matrix, where the nail originates. Melanin is deposited into the growing nail when melanocytes are activated, resulting in a pigmented band of melanonychia by transferring melanin-rich melanosomes

*Corresponding author: Yasmeen Jabeen Bhat, Department of Dermatology, Venereology and Leprosy, Government Medical College, Srinagar, Jammu and Kashmir, India. yasmeenatif76@gmail.com

Received: 01 November 2024 Accepted: 04 February 2025 Epub Ahead of Print: 17 April 2025 Published: 11 June 2025 DOI: 10.25259/JONS_30_2024

This is an open-access article distributed under the terms of the Creative Commons Attribution-Non Commercial-Share Alike 4.0 License, which allows others to remix, transform, and build upon the work non-commercially, as long as the author is credited and the new creations are licensed under the identical terms.

©2025 Published by Scientific Scholar on behalf of Journal of Onychology and Nail Surgery



Figure 1: Clinical image of longitudinal melanonychia.

to the differentiated matrix cells through dendrites.^[3] The pattern of nail pigmentation can be longitudinal presenting as a brown or black-grey band extending proximally from the nail matrix to the distal free edge of the nail plate; diffuse or total melanonychia with involvement of the entire nail plate by melanin; and transverse melanonychia involve transverse bands running across the width of the nail plate.^[1,3,4]

Dermoscopy is a non-invasive tool for differentiating benign and malignant melanonychia. In benign cases, findings include a pigmented band with regularly arranged parallel lines of similar colour and regular spacing and diameter. In malignant cases, this regular architecture is lost. The lines are brown to black, irregular and variable in intensity. Hutchinson sign may be positive,^[3,4] which refers to a pigmentation of the periungual tissue, including the nail folds. This is the true extension of melanin pigment from the nail matrix into the surrounding tissue. It can be strongly associated with subungual melanoma and warrants a biopsy.^[1,3] In contrast, the pseudo-Hutchinson sign involves pigmentation of the nail plate, seen through the surrounding periungual tissue, but does not involve it. It is an optical illusion due to the translucency of the nail fold, hyperpigmentation of the nail bed or nail plate reflection. Characterised by brown-grey to lighter pigmented lines, uniform colours and regular borders, it is generally associated with benign aetiologies and needs regular follow-up.^[1,3]

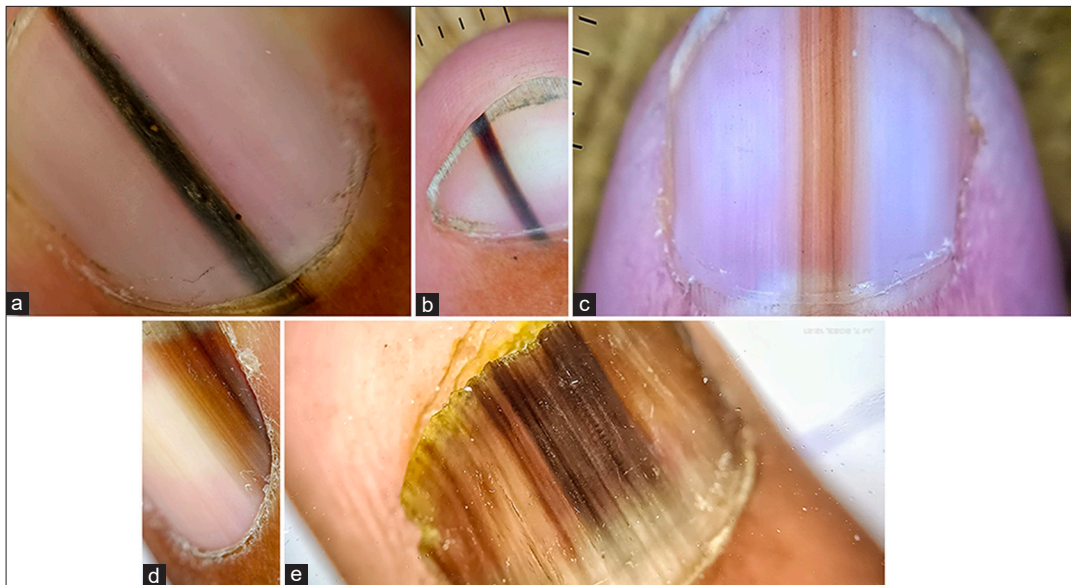


Figure 2: Dermoscopic images showing (a) longitudinal pigmented band (blackish) with regularly arranged parallel lines of similar colour, regular spacing and diameter with pseudo-Hutchinson sign present. (Dermlite DL4, ×10), (b) longitudinal pigmented band (black to brown) with regularly arranged parallel lines of similar colour, regular spacing and diameter with pseudo-Hutchinson sign present. (Dermlite DL4, ×10), (c) longitudinal pigmented band (light to dark brown) with regularly arranged parallel lines of similar colour, regular spacing and diameter with pseudo-Hutchinson sign present. (Dermlite DL4, ×10), (d) lateral longitudinal pigmented band (light to dark brown) with regularly arranged parallel lines of similar colour, regular spacing and diameter with pseudo-Hutchinson sign present. (Dermlite DL4, ×10), (e) longitudinal pigmented band involving whole nail (dark to light brown) with regularly arranged parallel lines of similar colour, regular spacing and diameter with pseudo-Hutchinson sign and yellowish subungual hyperkeratosis. (Dermlite DL4, ×10).

Table 1: Clinical and dermoscopic findings of five patients.

Case	History											
	Age	Gender	Symptoms	Duration (months)	Associated illness	Associated family history	Clinical examination	Dermoscopic examination	Pseudo-Hutchinson signs	Hutchinson signs	Subungual hyperkeratosis	Final diagnosis
1.	31	F	Blackish longitudinal discolouration of thumbnail	7	-	-	Longitudinal linear blackish pigmented band approximately measuring 2×0.5 cm.	Longitudinal blackish pigmented band with regularly arranged parallel lines of similar colour against a blackish background, regular spacing and diameter	+	-	-	Idiopathic benign longitudinal melanonychia
2.	26	F	Brownish longitudinal discolouration of thumbnail	9	-	-	Longitudinal linear brownish pigmented band approximately measuring 1.5×0.5 cm.	Longitudinal brownish pigmented band with regularly arranged parallel lines of similar colour against a brownish background, regular spacing and diameter	+	-	-	Idiopathic benign longitudinal melanonychia
3.	25	F	Brownish longitudinal discolouration of thumbnail	11	-	-	Longitudinal linear brownish pigmented band approximately measuring 1.5×0.5 cm.	Longitudinal brownish pigmented band with regularly arranged parallel lines of similar colour against a brownish background, regular spacing and diameter	+	-	-	Idiopathic benign longitudinal melanonychia
4.	34	M	Brownish longitudinal discolouration of thumbnail	14	-	-	Longitudinal linear brownish pigmented band approximately measuring 2×0.5 cm.	Longitudinal brownish pigmented band with regularly arranged parallel lines of similar colour against a brownish background, regular spacing and diameter	+	-	-	Idiopathic benign longitudinal melanonychia
5.	39	M	Brownish longitudinal discolouration involving the whole thumbnail	18	Type II Diabetes mellitus, Onychomycosis	+	Longitudinal linear brownish pigmented band involving the whole nail approximately measuring 2×2 cm with subungual hyperkeratosis.	Longitudinal brownish pigmented band involving whole nails with regularly arranged parallel lines of similar colour against a brownish background, regular spacing and diameter with subungual hyperkeratosis.	+	-	+	Fungal melanonychia in a longitudinal pattern

Other important clues include the micro-Hutchinson sign (subtle pigmentation or melanocytic extension into periungual tissues visible only on dermoscopy, it may be an early clue to subungual melanoma), triangle or delta sign (broader pigmentation proximally and tapering distally), blurred borders, colour variations, bandwidth more than 3 mm, parallel ridge sign (dark pigmentation along ridges and sparing of furrows), rapid growth and periungual erythema. These are clues to possible malignant changes and a biopsy and regular follow-up are needed.^[1-3]

Management includes categorising longitudinal melanonychia into low- and high-risk cases. Low-risk cases are to be kept on periodic follow-up and dermoscopic examinations every 6–12 months, while high-risk ones require more frequent visits at 3–6 months, and biopsy if suspicion of malignancy arises. Patients are to be aware of the early warning signs, including rapid change in pigmentation, an extension of pigment to periungual tissue or any pain and nail deformity.^[5]

CONCLUSION

Longitudinal melanonychia can be benign in adults with skin of color. Dermoscopy can be a valuable tool for differentiating benign from malignant melanonychia. It can also help check the progression of benign lesions and detect early malignant transformation.

Authors' contributions: All the authors' contributed to the design, literature search, concepts, data acquisition, data analysis, and manuscript editing, preparation and reviewing.

Ethical approval: Institutional Review Board approval is not required.

Declaration of patient consent: The authors certify that they have obtained all appropriate patient consent.

Financial support and sponsorship: Nil.

Conflicts of interest: Dr. Yasmeeen J. Bhat is on the editorial board of the Journal.

Use of artificial intelligence (AI)-assisted technology for manuscript preparation: The authors confirm that there was no use of artificial intelligence (AI)-assisted technology for assisting in the writing or editing of the manuscript and no images were manipulated using AI.

REFERENCES

1. Lee DK, Chang MJ, Desai AD, Lipner SR. Clinical and dermoscopic findings of benign longitudinal melanonychia due to melanocytic activation differ by skin type and predict likelihood of nail matrix biopsy. *J Am Acad Dermatol* 2022;87:792-9.
2. Khan K, Mavanur AA. Longitudinal melanonychia. *BMJ Case Rep* 2015;2015:bcr2015213459.
3. Singal A, Bisherwal K. Melanonychia: Etiology, diagnosis, and treatment. *Indian Dermatol Online J* 2020;11:1-11.
4. Leung AK, Robson WL, Liu EK, Kao CP, Fong JH, Leong AG, *et al.* Melanonychia striata in Chinese children and adults. *Int J Dermatol* 2007;46:920-2.
5. Mannava KA, Mannava S, Koman LA, Robinson-Bostom L, Jellinek N. Longitudinal melanonychia: Detection and management of nail melanoma. *Hand Surg* 2013;18:133-9.

How to cite this article: Ul Islam MS, Saqib NU, Danusari S, Sajad K, Bhat YJ. Benign longitudinal melanonychia in skin of color: A case series. *J Onychol Nail Surg.* 2025;2:37-40. doi: 10.25259/JONS_30_2024