

Definition-Pathogenesis risk factors-classification-scoring. In: Bertrand R, editor. Management of ingrowing nails. 1st ed. Basel, Switzerland: Springer International Publishing; 2016. p. 35-58.

4. Richert B, Caucanas M, Di Chiacchio N. Surgical approach to harpoon nail: A new variant of ingrowing toenail. *Dermatol Surg* 2014;40:700-1.
5. Sandhiya R, Rao R. "An uncanny kin of the ingrown toenail": Harpoon nail and the surgical challenge in its management. *J Cutan Aesthet Surg* 2020;13:142-4.

This is an open-access article distributed under the terms of the Creative Commons Attribution-Non Commercial-Share Alike 4.0 License, which allows others to remix, transform, and build upon the work non-commercially, as long as the author is credited and the new creations are licensed under the identical terms.

©2025 Published by Scientific Scholar on behalf of Journal of Onychology and Nail Surgery

How to cite this article: Chikkalagi CC, Grover C. Harpoon nail – A trespasser. *J Onychol Nail Surg.* 2025;2:50-2. doi: 10.25259/JONS_27_2024

Received: 04 October 2024 **Accepted:** 06 November 2024

Epub Ahead of Print: 22 January 2025 **Published:** 11 June 2025

DOI: 10.25259/JONS_27_2024

Reflections on brachyonychia: Insights and observations

Dear Editor,

A 22-year-old man presented to the dermatology clinic with concerns about abnormal nail and toe appearance. He reported that these changes had been present for as long as he could remember. His nails had always appeared shortened, without any associated pain or functional difficulties. There was no history of trauma or systemic illness. Additionally, the patient noted that the appearance of his toes was peculiar, particularly the 4th and 5th toes on both feet, which seemed to be shorter than normal. There was no history of onychotillomania and onychophagia. There was no significant medical history or any history of systemic disease. Also, there was no significant family history of similar nail or skeletal abnormalities and no known genetic disorders in the family.

On examination, all fingernails and toenails had brachyonychia, a condition identified as brachyonychia. The nails appeared to be shorter than the distal phalanx of each digit [Figures 1 and 2]. There was no evidence of discoloration, pitting, or other nail abnormalities. The 4th and 5th toes of both feet exhibited brachydactyly. The deformity was symmetrical and present on both feet [Figure 3]. No other bony abnormalities were noted in the patient.

On investigation, his parathyroid hormone (PTH), serum Vitamin D₃, thyroid-stimulating hormone (TSH), T₃, T₄, calcium, phosphorus and creatinine levels were normal. No specific genetic tests were performed at this visit. The X-ray of bilateral feet showed decreased length of phalanges of 4th and 5th digits of both feet. The clinical findings of brachyonychia affecting all fingers and toes, along with brachydactyly (shortened 4th and 5th toes) on both feet, suggest a possible congenital or genetic condition.

Racquet nail or brachyonychia was described by DuBois (1926) as a short, broad and flat nail plate with an altered shape resembling that of a tennis or squash racquet resulting

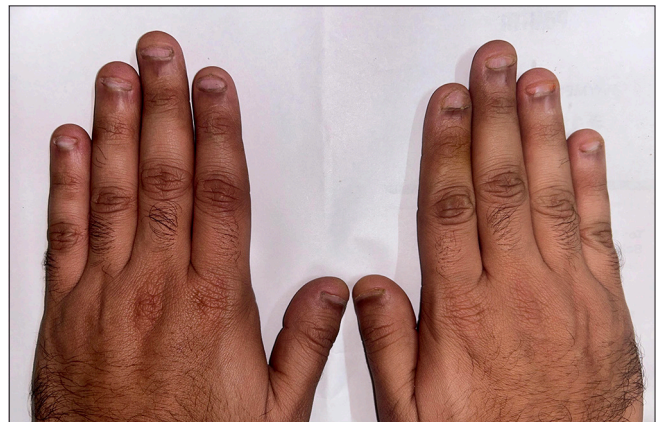

Figure 1: A 22-year-old male with brachyonychia involving all finger nails.

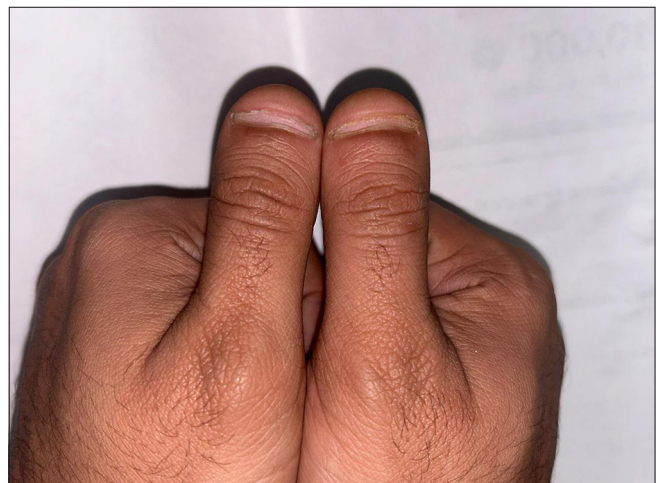


Figure 2: Close up of the patient's thumbs showing shortening of nail plate.

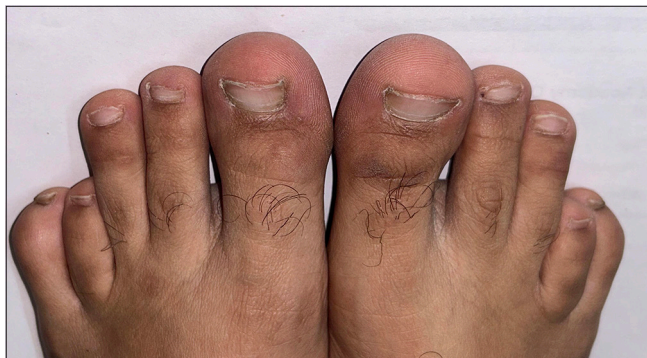

Figure 3: Bilaterally symmetrical brachydactyly of 4th and 5th toes and brachyonychia of all toenails.

from underlying bone and soft-tissue abnormalities of the terminal phalanges.^[1,2] It is a benign condition but can be genetic and acquired. The former is thought to result from alterations in the cartilage, which could include early closure of the cartilaginous line of the terminal phalanx, as suggested by Burrows, or obliteration of cartilage, as suggested by Oluf Thomsen.^[3] Hyperparathyroidism is the main cause of the acquired type of brachyonychia, according to Baran *et al.*^[4] Numerous conditions, such as malabsorption, rickets, osteomalacia, and chronic renal failure, maybe the cause of this condition.^[5] Brachyonychia and brachydactyly have been documented in a case of Bardet-Biedl syndrome, an autosomal recessive multisystem disorder characterised by a range of clinical features, including obesity, retinal degeneration, and renal anomalies.^[6]

Our case highlights the importance of a thorough evaluation for patients presenting with unusual nail and skeletal abnormalities. A multidisciplinary approach involving dermatology, orthopaedics, and genetics will be crucial in the accurate diagnosis and management of this patient's condition. Further investigation into potential genetic syndromes and their implications will be essential in providing comprehensive care.

Authors' contributions: YG: Conceptualisation, resources, validation, visualisation, writing; PS: Conceptualisation, resources, validation, visualisation, writing; NK: Formal analysis, investigation, resources, validation.



Ethical approval: Institutional Review Board approval is not required.

Declaration of patient consent: The authors certify that they have obtained all appropriate patient consent.

Financial support and sponsorship: Nil.

Conflicts of interest: Dr. Niti Khunger is on the Editorial Board of the Journal.

Use of artificial intelligence (AI)-assisted technology for manuscript preparation: The authors confirm that there was no use of artificial intelligence (AI)-assisted technology for assisting in the writing or editing of the manuscript and no images were manipulated using AI.

Yugansh Gautam, MBBS,¹, Prakhar Srivastava, MD, DNB,¹ 
, Niti Khunger, MD, DDV, DNB,¹ 

¹Department of Dermatology and STD, Vardhman Mahavir Medical College and Safdarjung Hospital, New Delhi, India.

*Corresponding author: Yugansh Gautam, Department of Dermatology and STD, Vardhman Mahavir Medical College and Safdarjung Hospital, New Delhi, India. ygautam98@gmail.com

REFERENCES

1. DuBois C. Quelques dystrophies localisées de l'hæterædo-syphilis. *AnnDerm Symp* 1926;7:415–25.
2. El-Komy MH, Baran R. Acroosteolysis presenting with brachyonychia following exposure to cold. *J Eur Acad Dermatol Venereol* 2015;29:2252-4.
3. Thomsen O. Hereditary growth anomaly of the thumb. *Hereditas* 1928;10:261–73.
4. Baran R, Turkmani MG, Mubki T. Acquired racquet nails: A useful sign of hyperparathyroidism. *J Eur Acad Dermatol Venereol* 2014;28:254-9.
5. Rasi A, Soltani-Arabshahi R, Naraghi Z. Circumscribed juvenile-onset pityriasis rubra pilaris with hypoparathyroidism and brachyonychia. *Cutis* 2006;77:218-22.
6. Detty SQ, Hinshaw MA, Tuite MJ, Means AD. Brachyonychia in a patient with Bardet-Biedl syndrome: Case report and review of this rare syndrome. *JAAD Case Rep* 2019;5:672-4.

This is an open-access article distributed under the terms of the Creative Commons Attribution-Non Commercial-Share Alike 4.0 License, which allows others to remix, transform, and build upon the work non-commercially, as long as the author is credited and the new creations are licensed under the identical terms.

©2025 Published by Scientific Scholar on behalf of Journal of Onychology and Nail Surgery

How to cite this article: Gautam Y, Srivastava P, Khunger N. Reflections on brachyonychia: Insights and observations. *J Onychol Nail Surg.* 2025;2:52-3. doi: 10.25259/JONS_28_2024

Received: 04 October 2024 **Accepted:** 12 December 2024

Epub Ahead of Print: 03 April 2025 **Published:** 11 June 2025

DOI: 10.25259/JONS_28_2024